

# Skin Manifestations Associated with COVID-19: Current Knowledge and Future Perspectives

Giovanni Genovese<sup>a, b</sup> Chiara Moltrasio<sup>a, c</sup> Emilio Berti<sup>a, b</sup>  
Angelo Valerio Marzano<sup>a, b</sup>

<sup>a</sup>Dermatology Unit, Fondazione IRCCS Ca' Granda Ospedale Maggiore Policlinico, Milan, Italy; <sup>b</sup>Department of Pathophysiology and Transplantation, Università degli Studi di Milano, Milan, Italy; <sup>c</sup>Department of Medical Surgical and Health Sciences, University of Trieste, Trieste, Italy

## Keywords

COVID-19 · Cutaneous manifestations · SARS-CoV-2

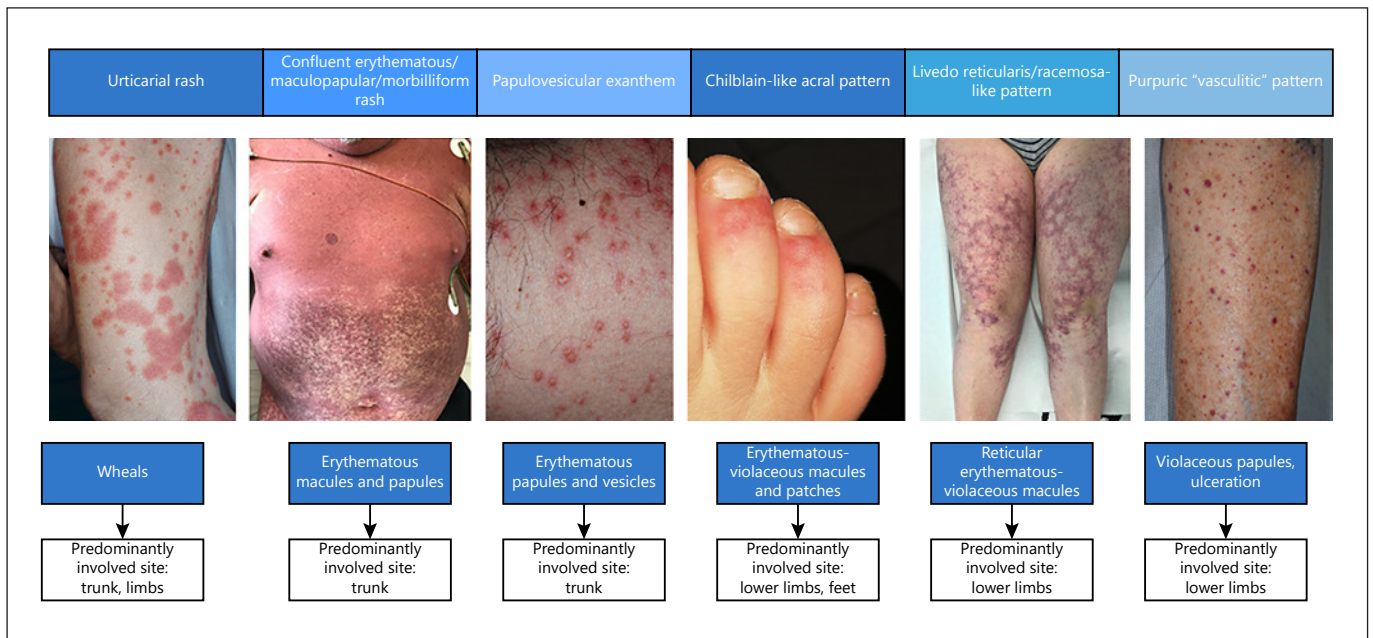
## Abstract

**Background:** Coronavirus disease-19 (COVID-19) is an ongoing global pandemic caused by the “severe acute respiratory syndrome coronavirus 2” (SARS-CoV-2), which was isolated for the first time in Wuhan (China) in December 2019. Common symptoms include fever, cough, fatigue, dyspnea and hypogeusia/hyposmia. Among extrapulmonary signs associated with COVID-19, dermatological manifestations have been increasingly reported in the last few months. **Summary:** The polymorphic nature of COVID-19-associated cutaneous manifestations led our group to propose a classification, which distinguishes the following six main clinical patterns: (i) urticarial rash, (ii) confluent erythematous/maculopapular/morbilliform rash, (iii) papulovesicular exanthem, (iv) chilblain-like acral pattern, (v) livedo reticularis/racemosa-like pattern, (vi) purpuric “vasculitic” pattern. This review summarizes the current knowledge on COVID-19-associated cutaneous manifestations, focusing on clinical features and therapeutic management of each category and attempting to give an overview of the hypothesized pathophysiological mechanisms of these conditions.

© 2020 S. Karger AG, Basel

## Introduction

In December 2019, a novel zoonotic RNA virus named “severe acute respiratory syndrome coronavirus 2” (SARS-CoV-2) was isolated in patients with pneumonia in Wuhan, China. Since then, the disease caused by this virus, called “coronavirus disease-19” (COVID-19), has spread throughout the world at a staggering speed becoming a pandemic emergency [1]. Although COVID-19 is best known for causing fever and respiratory symptoms, it has been reported to be associated also with different extrapulmonary manifestations, including dermatological signs [2]. Whilst the COVID-19-associated cutaneous manifestations have been increasingly reported, their exact incidence has yet to be estimated, their pathophysiological mechanisms are largely unknown, and the role, direct or indirect, of SARS-CoV-2 in their pathogenesis is still debated. Furthermore, evidence is accumulating that skin manifestations associated with COVID-19 are extremely polymorphic [3]. In this regard, our group proposed the following six main clinical patterns of COVID-19-associated cutaneous manifestations in a recently published review article: (i) urticarial rash, (ii) confluent erythematous/maculopapular/morbilliform rash, (iii) papulovesicular exanthem, (iv) chilblain-like acral pattern, (v) livedo reticularis/racemosa-like pat-



**Fig. 1.** Clinical features of COVID-19-associated cutaneous manifestations.

tern, (vi) purpuric “vasculitic” pattern (shown in Fig. 1) [2]. Other authors have attempted to bring clarity in this field, suggesting possible classifications of COVID-19-associated cutaneous manifestations [4–6]. Finally, distinguishing nosological entities “truly” associated with COVID-19 from cutaneous drug reactions or exanthems due to viruses other than SARS-CoV-2 remains a frequent open problem.

Herein, we have striven to provide a comprehensive overview of the cutaneous manifestations associated with COVID-19 subdivided according to the classification by Marzano et al. [2], focusing on clinical features, histopathological features, hypothesized pathophysiological mechanisms and therapeutic management.

## Urticarial Rash

### *Clinical Features and Association with COVID-19 Severity*

It is well known that urticaria and angioedema can be triggered by viral and bacterial agents, such as cytomegalovirus, herpesvirus, and Epstein-Barr virus and mycoplasma. However, establishing a cause-effect relationship may be difficult in single cases [7, 8]. Urticarial eruptions associated with COVID-19 have been first reported by Recalcati [9] in his cohort of hospitalized patients, accounting for 16.7% of total skin manifestations. Urticar-

ia-like eruptions have been subsequently described in other cohort studies. Galván Casas et al. [4] stated that urticarial rash occurred in 19% of their cohort, tended to appear simultaneously with systemic symptoms, lasted approximately 1 week and was associated with medium-high severity of COVID-19. Moreover, itch was almost always present [4]. Freeman et al. [10] found a similar prevalence of urticaria (16%) in their series of 716 cases, in which urticarial lesions predominantly involved the trunk and limbs, relatively sparing the acral sites. As shown in Table 1, urticaria-like signs accounted for 11.9% of cutaneous manifestations seen in an Italian multicentric cohort study on 159 patients [unpubl. data]. Urticarial lesions associated with fever were reported to be early or even prodromal signs of COVID-19, in the absence of respiratory symptoms, in 3 patients [11–13]. Therefore, the authors of the reports suggested that isolation is needed for patients developing such skin symptoms if COVID-19 infection is suspected in order to prevent possible SARS-CoV-2 transmission [11–13]. COVID-19-related urticaria occurred also in a familial cluster, involving 2 patients belonging to a Mexican family of 5 people, all infected by SARS-CoV-2 and suffering also from anosmia, ageusia, chills and dizziness [14]. Angioedema may accompany COVID-19-related urticaria, as evidenced by the case published in June 2020 of an elderly man presenting with urticaria, angioedema, general malaise, fatigue,

**Table 1.** Prevalence of different clinical patterns in the main studies on COVID-19-associated cutaneous manifestations

First author (total size of study population)	Number of patients with urticarial rash (%)	Number of patients with confluent erythematous/maculopapular/morbilloform rash (%)	Number of patients with papulo-vesicular exanthem (%)	Number of patients with chilblain-like acral pattern (%)	Number of patients with livedo reticularis/racemosa-like pattern (%)	Number of patients with purpuric "vasculitic" pattern (%)
Galván Casas [4] (375)	73 (19)	176 (47)	34 (9)	71 (19)	21 (6)	
Freeman [10] (716)	55 (8.1)	115 (16.1)	49 (7.2)	422 (62)	46 (6.4)	51 (7.1)
Askin [29] (52)	7 (13.5)	29 (55.8)	3 (5.8)	1 (1.9)	0	8 (15.4)
De Giorgi [20] (53)	14 (26)	37 (70)	2 (4)	0	0	0
Unpublished data from an Italian multicentric study (159)	19 (11.9)	48 (30.2)	29 (18.2)	46 (28.9)	4 (2.5)	13 (8.2)

fever and pharyngodynia [15]. Urticarial vasculitis has also been described in association with COVID-19 in 2 patients [16].

#### *Histopathological Findings*

Histopathological studies of urticarial rashes are scant. In a 60-year-old woman with persistent urticarial eruption and interstitial pneumonia who was not under any medication, Rodriguez-Jiménez et al. [17] found on histopathology slight vacuolar interface dermatitis with occasional necrotic keratinocytes curiously compatible with an erythema multiforme-like pattern. Amatore et al. [18] documented also the presence of lichenoid and vacuolar interface dermatitis, associated with mild spongiosis, dyskeratotic basal keratinocytes and superficial perivascular lymphocytic infiltrate, in a biopsy of urticarial eruption associated with COVID-19 (Fig. 2).

#### *Therapeutic Options*

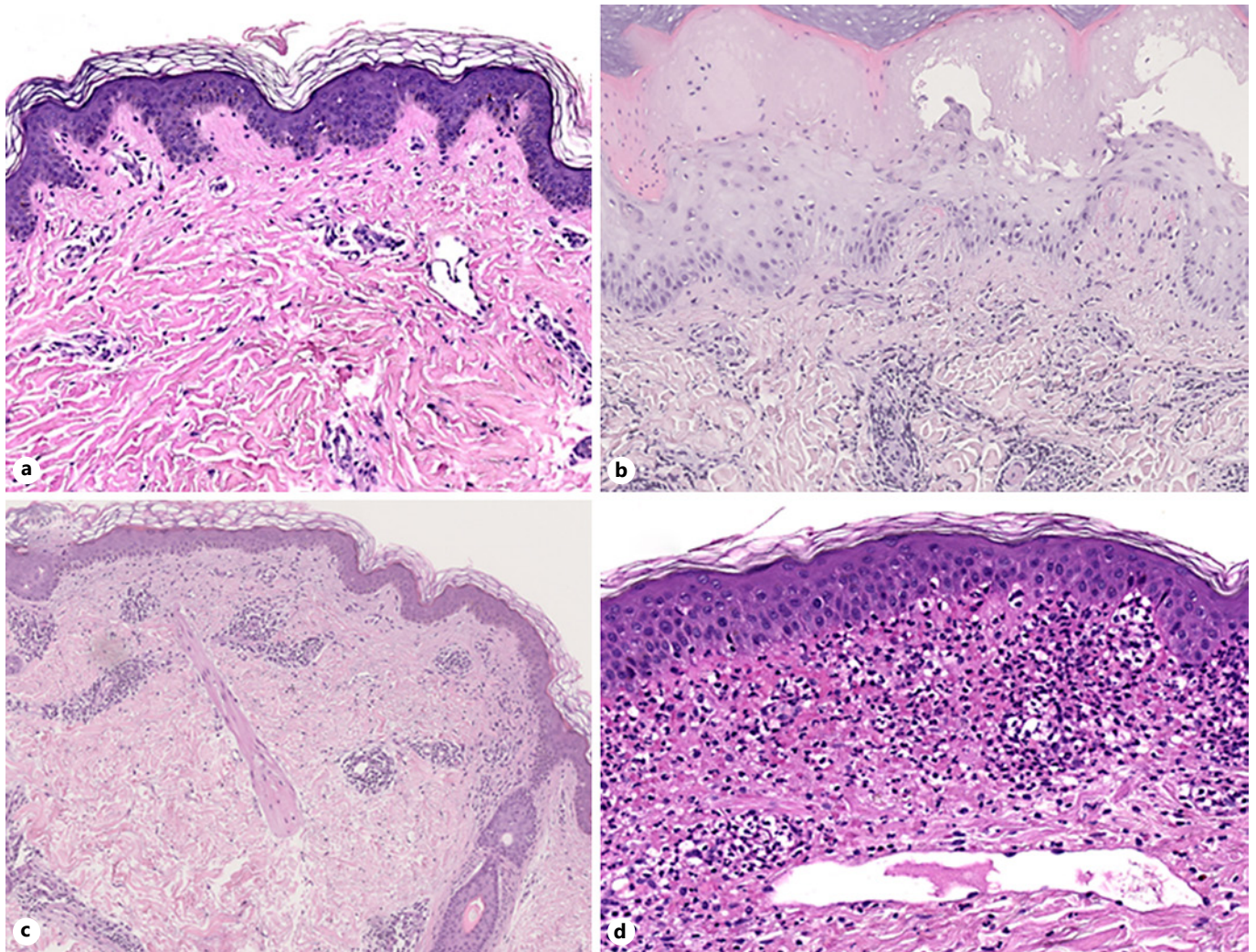
Shanshal [19] suggested low-dose systemic corticosteroids as a therapeutic option for COVID-19-associated urticarial rash. Indeed, the author hypothesized that low-dose systemic corticosteroids, combined with non-sedating antihistamines, can help in managing the hyperactivity of the immune system in COVID-19, not only to control urticaria, but also to improve possibly the survival rate in COVID-19.

### **Confluent Erythematous/Maculopapular/Morbilloform Rash**

#### *Clinical Features and Association with COVID-19 Severity*

Maculopapular eruptions accounted for 47% of all cutaneous manifestations in the cohort of Galván Casas et

al. [4], for 44% of the skin manifestations included in the study by Freeman et al. [10], who further subdivided this group of cutaneous lesions into macular erythema (13%), morbilliform exanthems (22%) and papulosquamous lesions (9%), and for 30.2% of the cutaneous manifestations included in the unpublished Italian multicentric study shown in Table 1. The prevalence of erythematous rash was higher in other studies, like that published by De Giorgi et al. [20] in May 2020, in which erythematous rashes accounted for 70% of total skin manifestations. In the series by Freeman et al. [10], macular erythema, morbilliform exanthems and papulosquamous lesions were predominantly localized on the trunk and limbs, being associated with pruritus in most cases. In the same series, these lesions occurred more frequently after COVID-19 systemic symptoms' onset [21]. The clinical picture of the eruptions belonging to this group may range from erythematous confluent rashes to maculopapular eruptions and morbilliform exanthems. Erythematous lesions may show a purpuric evolution [21] or coexist from the beginning with purpuric lesions [22]. Erythematous papules may also be arranged in a morbilliform pattern [23]. In a subanalysis of the COVID-Piel Study [4] on maculopapular eruptions including also purpuric, erythema multiforme-like, pityriasis rosea-like, erythema elevatum diutinum-like and perifollicular eruptions, morbilliform exanthems were the most frequent maculopapular pattern ( $n = 80/176$ , 45.5%) [24]. This study showed that in most cases lesions were generalized, symmetrical and started on the trunk with centrifugal progression. In the same subanalysis, hospital admission due to pneumonia was very frequent (80%) in patients with a morbilliform pattern [24]. In this group, the main differential diagnoses are represented by exanthems due to viruses other than SARS-CoV-2 and drug-induced cutaneous reactions.



**Fig. 2.** Histopathological features of the main cutaneous patterns associated with COVID-19. **a** Urticarial rash. **b** Confluent erythematous maculopapular/morbilliform rash. **c** Chilblain-like acral lesions. **d** Purpuric “vasculitic” pattern.

### *Histopathological Findings*

Histopathology of erythematous eruptions was described by Gianotti et al. [25], who found vascular damage in all the 3 cases examined. A clinicopathological characterization of late-onset maculopapular eruptions related to COVID-19 was provided also by Reymundo et al. [26], who observed a mild superficial perivascular lymphocytic infiltrate on the histology of 4 patients. In contrast, Herrero-Moyano et al. [27] observed dense neutrophilic infiltrates in 8 patients with late maculopapular eruptions. The authors of the former study postulated that this discrepancy could be attributable to the history of new drug assumptions in the series of Herrero-Moyano et al. [26] (Fig. 2).

### *Therapeutic Options*

The management of confluent erythematous/maculopapular/morbilliform rash varies according to the severity of the clinical picture. Topical corticosteroids can be sufficient in most cases [23], systemic corticosteroids deserving to be administered just in more severe and widespread presentations.

### **Papulovesicular Exanthem**

*Clinical Features and Association with COVID-19 Severity*  
 COVID-19-associated papulovesicular exanthem was first extensively reported in a multicenter Italian

case series of 22 patients published in April 2020 [28]. In this article, it was originally described as “varicella-like” due to resemblance of its elementary lesions to those of varicella. However, the authors themselves underlined that the main clinical features of COVID-19-associated papulovesicular exanthem, namely trunk involvement, scattered distribution and mild/absent pruritus, differentiated it from “true” varicella. In this study, skin lesions appeared on average 3 days after systemic symptoms’ onset and healed after 8 days, without scarring sequelae [28]. The exact prevalence of papulovesicular exanthems is variable. Indeed, in a cohort of 375 patients with COVID-19-associated cutaneous manifestations [4], patients with papulovesicular exanthem were 34 (9%), while they were 3 out of 52 (5.8%), 1 out of 18 (5.5%) and 2 out of 53 (4%) in the cohorts published by Askin et al. [29], Recalcati [9] and De Giorgi et al. [20], respectively. In the Italian multicentric study shown in Table 1, papulovesicular rash accounted for 18.2% of skin manifestations. Furthermore, even if papulovesicular exanthem tends to involve more frequently the adult population, with a median age of 60 years in the study by Marzano et al. [28], also children may be affected [30]. Galván Casas et al. [4] reported that vesicular lesions generally involved middle-aged patients, before systemic symptoms’ onset in 15% of cases, and were associated with intermediate COVID-19 severity. Fernandez-Nieto et al. [31] conducted a prospective study on 24 patients diagnosed with COVID-19-associated vesicular rash. In this cohort, the median age (40.5 years) was lower than that reported by Marzano et al. [28], and COVID-19 severity was mostly mild or intermediate, with only 1 patient requiring intensive unit care support. In our cohort of 22 patients, a patient was hospitalized in the intensive care unit and 3 patients died [28]. Vesicular rash, which was generally pruritic, appeared after COVID-19 diagnosis in most patients ( $n = 19$ ; 79.2%), with a median latency time of 14 days [31]. Two different morphological patterns were found: a widespread polymorphic pattern, more common and consisting of small papules, vesicles and pustules of different sizes, and a localized pattern, less frequent and consisting of monomorphic lesions, usually involving the mid chest/upper abdominal region or the back [31].

#### *Histopathological Findings*

Mahé et al. [32] reported on 3 patients with typical COVID-19-associated papulovesicular rash, in which the histological pattern of skin lesions showed promi-

nent acantholysis and dyskeratosis associated with the presence of an unilocular intraepidermal vesicle in a suprabasal location. Based on these histopathological findings, the authors refused the term “varicella-like rash” and proposed a term which was more suitable in their view: “COVID-19-associated acantholytic rash.” Histopathological findings of another case of papulovesicular eruption revealed extensive epidermal necrosis with acantholysis and swelling of keratinocytes, ballooning degeneration of keratinocytes and signs of endotheliitis in the dermal vessels [33]. Acantholysis and ballooned keratinocytes were found also by Fernandez-Nieto et al. [31] in 2 patients.

The differential diagnosis with infections caused by members of the *Herpesviridae* family has been much debated. Tammaro et al. [34] described the onset of numerous, isolated vesicles on the back 8 days after COVID-19 diagnosis in a Barcelonan woman and reported on 2 patients from Rome presenting with isolated, mildly pruritic erythematous-vesicular lesions on their trunk, speculating that these manifestations might be due to viruses belonging to the Herpesviridae family. On the other hand, classic herpes zoster has been reported to complicate the course of COVID-19 [35].

The controversy regarding the role of herpesvirus in the etiology of papulovesicular exanthems fuelled an intense scientific debate. Indeed, some authors raised the question whether papulovesicular exanthem associated with COVID-19 could be diagnosed without ruling out varicella zoster virus and herpes simplex virus with Tzanck smear or polymerase chain reaction (PCR) for the Herpesviridae family in the vesicle fluid or on the skin [36, 37]. In our opinion, even if seeking DNA of Herpesviridae family members is ideally advisable, clinical diagnosis may be reliable in most cases, and the role of herpes viruses as mere superinfection in patients with dysfunctional immune response associated with COVID-19 needs to be considered [38]. To our knowledge, SARS-CoV-2 has not been hitherto isolated by means of reverse transcriptase PCR in the vesicle fluid of papulovesicular rash [33, 31].

#### *Therapeutic Options*

No standardized treatments for COVID-19-related papulovesicular exanthem are available, also given that it is self-healing within a short time frame. Thus, a “wait-and-see” strategy may be recommended.

## Chilblain-Like Acral Pattern

### *Clinical Features and Association with COVID-19 Severity*

COVID-19-related chilblain-like acral lesions have been first described in a 13-year-old boy by Italian authors in early March [39]. Since then, several “outbreaks” of chilblain-like acral lesions chiefly involving young adults and children from different countries worldwide have been posted on social media and published in the scientific literature [40–46]. Caucasians seem to be significantly more affected than other ethnic groups [47, 48]. Chilblain-like acral lesions were the second most frequent cutaneous manifestation ( $n = 46/159$ ; 28.9%) in the multicenter Italian study shown in Table 1. Different pathogenetic hypotheses, including increased interferon release induced by COVID-19 and consequent cytokine-mediated inflammatory response, have been suggested [49]. Furthermore, virus-induced endothelial damage as well as an obliterative microangiopathy and coagulation abnormalities could be mechanisms involved in the pathogenesis of these lesions [50]. Chilblain-like acral lesions associated with COVID-19 were depicted as erythematous-violaceous patches or plaques predominantly involving the feet and, to a lesser extent, hands [40, 51]. Rare cases of chilblain-like lesions involving other acral sites, such as the auricular region, were also reported [52]. The occurrence of blistering lesions varied according to the case series analyzed; Piccolo et al. [51], indeed, reported the presence of blistering lesions in 23 out of 54 patients, while other authors did not describe bullous lesions in their series [40, 47]. Dermoscopy of these lesions revealed the presence of an indicative pattern represented by a red background area with purpuric globules [53]. Pain/burning sensation as well as pruritus were commonly reported symptoms, even if a small proportion of patients presented with asymptomatic lesions [40, 44, 47]. Unlike other COVID-19-related cutaneous findings, chilblain-like acral lesions tended to mostly involve patients without systemic symptoms.

The frequent occurrence of chilblain-like lesions in the absence of cold exposure and the involvement of patients without evident COVID-19-related symptoms raised the question whether these manifestations were actually associated with SARS-CoV-2 infection.

### *Histopathological and Pathophysiological Findings*

Chilblain-like lesions share many histopathological features with idiopathic and autoimmunity-related chilblains, including epidermal necrotic keratinocytes, dermal edema,

perivascular and perieccrine sweat gland lymphocytic inflammation. Vascular changes such as endotheliitis and microthrombi may be found [40, 45, 54, 55] (Fig. 2).

Data on the real association between chilblain-like acral lesions and COVID-19 are controversial.

The first case series failed to perform SARS-CoV-2 testing in all patients, also due to logistic problems and economic restrictions, and diagnosed COVID-19 only in a minority of patients with chilblain-like acral lesions [40, 44, 47]. Subsequently, some authors systematically sought SARS-CoV-2 with serology and/or nasopharyngeal swab in patients with chilblain-like acral lesions. In their cohort of 38 children with pseudo-chilblain, Caselli et al. [56] showed no evidence of SARS-CoV-2 infection by PCR or serology. Chilblain-like acral lesions appeared not to be directly associated with COVID-19 also in the case series by Herman et al. [57]. These authors failed to detect SARS-CoV-2 in nasopharyngeal swabs and skin biopsies and demonstrated no specific anti-SARS-CoV-2 immunoglobulin IgM or IgG antibodies in blood samples. Therefore, they concluded that lifestyle changes associated with lockdown measures might be a possible explanation for these lesions [57]. Similar results were obtained also by other authors [58–63] weakening the hypothesis of a direct etiological link between SARS-CoV-2 and chilblain-like acral lesions.

Opposite conclusions have been drawn by Colmenero et al. [64], who demonstrated by immunohistochemistry and electron microscopy the presence of SARS-CoV-2 in endothelial cells of skin biopsies of 7 children with chilblain-like acral lesions, suggesting that virus-induced vascular damage and secondary ischemia could explain the pathophysiology of these lesions.

In the absence of definitive data on chilblain-like acral lesions’ pathogenesis, the occurrence of such lesions should prompt self-isolation and confirmatory testing for SARS-CoV-2 infection [65].

### *Therapeutic Options*

In the absence of significant therapeutic options for chilblain-like acral lesions associated with COVID-19 and given their tendency to spontaneously heal, a “wait-and-see” strategy may be suggested.

## Livedo Reticularis/Racemosa-Like Pattern

### *Clinical Features and Association with COVID-19 Severity*

Livedo describes a reticulate pattern of slow blood flow, with consequent desaturation of blood and bluish

cutaneous discoloration. It has been divided into: (i) livedo reticularis, which develops as tight, symmetrical, lace-like, dusky patches forming complete rings surrounding a pale center, generally associated with cold-induced cutaneous vasoconstriction or vascular flow disturbances such as seen in polycythemia and (ii) livedo racemosa, characterized by larger, irregular and asymmetrical rings than seen in livedo reticularis, more frequently associated with focal impairment of blood flow, as it can be seen in Sneddon's syndrome [66].

In our classification, the livedo reticularis/racemosa-like pattern has been distinguished by the purpuric "vasculitic" pattern because the former likely recognizes an occlusive/microthrombotic vasculopathic etiology, while the latter can be more likely considered the expression of a "true" vasculitic process [2]. Instead, the classification by Galván Casas et al. [4] merged these two patterns into the category "livedo/necrosis".

In a French study on vascular lesions associated with COVID-19, livedo was observed in 1 out of 7 patients [43]. In the large cases series of 716 patients by Freeman et al. [10], livedo reticularis-like lesions, retiform purpura and livedo racemosa-like lesions accounted for 3.5, 2.6 and 0.6% of all cutaneous manifestations, respectively. In the multicentric Italian study, livedo reticularis/racemosa-like lesions accounted for 2.5% of cutaneous manifestations (Table 1).

The pathogenic mechanisms at the basis of small blood vessel occlusion are yet unknown, even if neurogenic, microthrombotic or immune complex-mediated etiologies have been postulated [67].

Livedo reticularis-like lesions are frequently mild, transient and not associated with thromboembolic complications [68, 69]. On the contrary, livedo racemosa-like lesions and retiform purpura have often been described in patients with severe coagulopathy [60–72].

#### *Histopathological and Pathophysiological Findings*

The histopathology of livedoid lesions associated with COVID-19 has been described by Magro et al. [73], who observed in 3 patients pauci-inflammatory microthrombotic vasculopathy. The same group demonstrated that in the thrombotic retiform purpura of patients with severe COVID-19, the vascular thrombosis in the skin and internal organs is associated with a minimal interferon response permitting increased viral replication with release of viral proteins that localize to the endothelium inducing widespread complement activation [74], which is frequent in COVID-19 patients and probably involved in the pathophysiology of its clinical complications [75].

#### *Therapeutic Options*

In view of the absence of significant therapeutic options for livedo reticularis/racemosa-like lesions associated with COVID-19, a "wait-and-see" strategy may be suggested.

### **Purpuric "Vasculitic" Pattern**

#### *Clinical Features and Association with COVID-19 Severity*

The first COVID-19-associated cutaneous manifestation with purpuric features was reported by Joob et al. [76], who described a petechial rash misdiagnosed as dengue in a COVID-19 patient. Purpuric lesions have been suggested to occur more frequently in elderly patients with severe COVID-19, likely representing the cutaneous manifestations associated with the highest rate of COVID-19-related mortality [4]. This hypothesis is corroborated by the unfavorable prognosis observed in several cases reported in the literature [77, 78].

The purpuric pattern reflects the presence of vasculitic changes probably due to the direct damage of endothelial cells by the virus or dysregulated host inflammatory responses induced by COVID-19.

These lesions are likely to be very rare, representing 8.2% of skin manifestations included in the Italian multicentric study shown in Table 1. In their case series of 7 patients with vascular skin lesions related to COVID-19, Bouaziz et al. [43] reported 2 patients with purpuric lesions with ( $n = 1$ ) and without ( $n = 1$ ) necrosis. In the series by Freeman et al. [10], 12/716 (1.8%) and 11/716 (1.6%) cases of patients with palpable purpura and dengue-like eruption, respectively, have been reported. Galván Casas et al. [4] reported 21 patients with "livedo/necrosis," most of whom presenting cutaneous signs in concomitance with systemic symptoms' onset.

Purpuric lesions may be generalized [79], localized in the intertriginous regions [80] or arranged in an acral distribution [81]. Vasculitic lesions may evolve into hemorrhagic blisters [77]. In most severe cases, extensive acute necrosis and association with severe coagulopathy may be seen [78]. Dermoscopy of purpuric lesions revealed the presence of papules with incomplete violaceous rim and a central yellow globule [82].

#### *Histopathological Findings*

When performed, histopathology of skin lesions showed leukocytoclastic vasculitis [77, 79], severe neutrophilic infiltrate within the small vessel walls and in their

**Table 2.** Summary of clinical features, histopathological findings, severity of COVID-19 systemic symptoms and therapeutic options of COVID-19-related skin manifestations

	Clinical features	COVID-19 severity	Histopathological findings	Therapeutic options
Urticarial rash	Itching urticarial rash predominantly involving the trunk and limbs; angioedema may also rarely occur	Intermediate severity	Vacuolar interface dermatitis associated with superficial perivascular lymphocytic infiltrate	Low-dose systemic corticosteroids combined with non-sedating antihistamines
Confluent erythematous/maculopapular/morbilliform rash	Generalized, symmetrical lesions starting from the trunk with centrifugal progression; purpuric lesions may coexist from the onset or develop during the course of the skin eruption	Intermediate severity	Superficial perivascular lymphocytic and/or neutrophilic infiltrate	Topical corticosteroids for mild cases; systemic corticosteroids for severe cases
Papulovesicular exanthem	(i) Widespread polymorphic pattern consisting of small papules, vesicles and pustules of different sizes; (ii) localized pattern consisting of papulovesicular lesions, usually involving the mid chest/upper abdominal region or the back	Intermediate severity	Prominent acantholysis and dyskeratosis associated with unilocular intraepidermal vesicles in a suprabasal location	Wait and see
Chilblain-like acral pattern	Erythematous-violaceous patches or plaques predominantly involving the feet or, to a lesser extent, hands. Pain/burning sensation as well as pruritus were commonly reported symptoms	Asymptomatic status	Perivascular and periadnexal dermal lymphocytic infiltrates	Wait and see
Livedo reticularis/racemosa-like pattern	Livedo reticularis-like lesions: mild, transient, symmetrical, lace-like, dusky patches forming complete rings surrounding a pale center. Livedo racemosa-like lesions: large, irregular and asymmetrical violaceous annular lesions frequently described in patients with severe coagulopathy	Livedo reticularis-like lesions: intermediate severity; livedo racemosa-like lesions: high severity	Pauci-inflammatory microthrombotic vasculopathy	Wait and see
Purpuric “vasculitic” pattern	Purpuric lesions may be generalized, arranged in an acral distribution or localized in the intertriginous regions. Purpuric elements may evolve into hemorrhagic blisters, possibly leading to necrotic-ulcerative lesions	High severity	Leukocytoclastic vasculitis, severe perivascular neutrophilic and lymphocytic infiltrate, presence of fibrin and endothelial swelling	Topical corticosteroids for mild cases; systemic corticosteroids for severe cases

The correlation between severity of COVID-19 systemic symptoms and skin manifestations has been inferred mainly from the study by Freeman et al. [10].

proximity [77], intense lymphocytic perivascular infiltrates [81], presence of fibrin [79, 81] and endothelial swelling [82] (Fig. 2).

### Therapeutic Options

Topical corticosteroids have been successfully used for treating mild cases of purpuric lesions [80]. Cases with necrotic-ulcerative lesions and widespread presentation may be treated with systemic corticosteroids.

### Other COVID-19-Associated Cutaneous Manifestations

Other peculiar rare COVID-19-related cutaneous manifestations that cannot be pigeonholed in the classification proposed by our group [2] include, among others, the erythema multiforme-like eruption [83], pityriasis rosea-like rash [84], multi-system inflammatory syndrome in children [85], anagen effluvium [86] and a pseudoherpetic variant of Grover disease [87]. However, the spectrum of possible COVID-19-associated skin manifesta-



tions is likely to be still incomplete, and it is expected that new entities associated with this infection will be described.

## Conclusion

COVID-19-associated cutaneous manifestations have been increasingly reported in the last few months, garnering attention both from the international scientific community and from the media. A few months after the outbreak of the pandemic, many narrative and systematic reviews concerning the dermatological manifestations of COVID-19 have been published [2, 3, 6, 88–91]. A summary of clinical features, histopathological findings, severity of COVID-19 systemic symptoms and therapeutic options of COVID-19-related skin manifestations has been provided in Table 2.

Albeit several hypotheses on pathophysiological mechanisms at the basis of these skin findings are present in the literature [50, 92, 93], none of them is substantiated by strong evidence, and this field needs to be largely elucidated. Moreover, cutaneous eruptions due to viruses other than SARS-CoV-2 [35, 37] or drugs prescribed for the management of this infection [94, 95] always need to be ruled out.

Experimental pathophysiological studies and clinical data derived from large case series are still needed for shedding light onto this novel, underexplored and fascinating topic.

## References

- 1 Huang C, Wang Y, Li X, Ren L, Zhao J, Hu Y, et al. Clinical features of patients infected with 2019 novel coronavirus in Wuhan, China. *Lancet*. 2020 Feb;395(10223):497–506.
- 2 Marzano AV, Cassano N, Genovese G, Moltrasio C, Vena GA. Cutaneous manifestations in patients with COVID-19: a preliminary review of an emerging issue. *Br J Dermatol*. 2020 Sep;183(3):431–42.
- 3 Matar S, Oulès B, Sohier P, Chosidow O, Beylot-Barry M, Dupin N, et al. Cutaneous manifestations in SARS-CoV-2 infection (COVID-19): a French experience and a systematic review of the literature. *J Eur Acad Dermatol Venereol*. 2020 Jun;jdv.16775.
- 4 Galván Casas C, Català A, Carretero Hernández G, Rodríguez-Jiménez P, Fernández-Nieto D, Rodríguez-Villa Lario A, et al. Classification of the cutaneous manifestations of COVID-19: a rapid prospective nationwide consensus study in Spain with 375 cases. *Br J Dermatol*. 2020 Jul;183(1):71–7.
- 5 Potekaev NN, Zhukova OV, Protsenko DN, Demina OM, Khlystova EA, Bogin V. Clinical characteristics of dermatologic manifestations of COVID-19 infection: case series of 15 patients, review of literature, and proposed etiological classification. *Int J Dermatol*. 2020 Aug;59(8):1000–9.
- 6 Gisondi P, Plaserico S, Bordin C, Alaibac M, Girolomoni G, Naldi L. Cutaneous manifestations of SARS-CoV-2 infection: a clinical update [online ahead of print]. *J Eur Acad Dermatol Venereol*. 2020 Jun;jdv.16774.
- 7 Imbalzano E, Casciaro M, Quartuccio S, Minicullo PL, Cascio A, Calapai G, et al. Association between urticaria and virus infections: A systematic review. *Allergy Asthma Proc*. 2016 Jan-Feb;37(1):18–22.
- 8 Yong SB, Yeh WC, Wu HJ, Chen HH, Huang JY, Chang TM, et al. Impact of mycoplasma pneumonia infection on urticaria: A nationwide, population-based retrospective cohort study in Taiwan. *PLoS One*. 2019 Dec;14(12):e0226759.
- 9 Recalcati S. Cutaneous manifestations in COVID-19: a first perspective. *J Eur Acad Dermatol Venereol*. 2020 May;34(5):e212–3.
- 10 Freeman EE, McMahon DE, Lipoff JB, Rosenbach M, Kovarik C, Desai SR, et al. The spectrum of COVID-19-associated dermatologic manifestations: an international registry of 716 patients from 31 countries. *J Am Acad Dermatol*. 2020 Oct;83(4):1118–29.
- 11 van Damme C, Berlingin E, Saussez S, Accaputo O. Acute urticaria with pyrexia as the first manifestations of a COVID-19 infection. *J Eur Acad Dermatol Venereol*. 2020 Jul;34(7):e300–1.
- 12 Quintana-Castanedo L, Feito-Rodríguez M, Valero-López I, Chiloeches-Fernández C, Sendagorta-Cudós E, Herranz-Pinto P. Urticarial exanthem as early diagnostic clue for COVID-19 infection. *JAAD Case Rep*. 2020 Apr;6(6):498–9.

## Key Message

Although COVID-19-associated cutaneous manifestations have been increasingly reported, their pathophysiological mechanisms need to be extensively explored. The conditions may be distinguished in six clinical phenotypes, each showing different histopathological patterns.

## Acknowledgment

We would like to thank Dr. Cosimo Misciali, Dr. Paolo Sena and Prof. Pietro Quaglino for kindly providing us with histopathological pictures.

## Conflict of Interest Statement

The authors have no conflicts of interest to declare.

## Funding Sources

This paper did not receive any funding.

## Author Contributions

Giovanni Genovese wrote the paper with the contribution of Chiara Moltrasio. Angelo Valerio Marzano and Emilio Berti supervised the work and revised the paper for critical revision of important intellectual content.

- 13 Hassan K. Urticaria and angioedema as a prodromal cutaneous manifestation of SARS-CoV-2 (COVID-19) infection. *BMJ Case Rep*. 2020 Jul;13(7):e236981.
- 14 Cepeda-Valdes R, Carrion-Alvarez D, Trejo-Castro A, Hernandez-Torre M, Salas-Alanis J. Cutaneous manifestations in COVID-19: familial cluster of urticarial rash. *Clin Exp Dermatol*. 2020 May;45(7):895-6.
- 15 Najafzadeh M, Shahzad F, Ghaderi N, Ansari K, Jacob B, Wright A. Urticaria (angioedema) and COVID-19 infection. *J Eur Acad Dermatol Venereol*. 2020 Oct;34(10):e568-70.
- 16 de Perosanz-Lobo D, Fernandez-Nieto D, Burgos-Blasco P, Selda-Enriquez G, Carretero I, Moreno C, et al. Urticarial vasculitis in COVID-19 infection: a vasculopathy-related symptom? *J Eur Acad Dermatol Venereol*. 2020 Oct;34(10):e566-8.
- 17 Rodríguez-Jiménez P, Chicharro P, De Argila D, Muñoz-Hernández P, Llamas-Velasco M. Urticaria-like lesions in COVID-19 patients are not really urticaria - a case with clinicopathological correlation. *J Eur Acad Dermatol Venereol*. 2020 May;34(9): <https://doi.org/10.1111/jdv.16618>.
- 18 Amatore F, Macagno N, Mailhe M, Demarez B, Gaudy-Marqueste C, Grob JJ, et al. SARS-CoV-2 infection presenting as a febrile rash. *J Eur Acad Dermatol Venereol*. 2020 Jul;34(7):e304-6.
- 19 Shanshal M. Low-dose systemic steroids, an emerging therapeutic option for COVID-19-related urticaria. *J Dermatolog Treat*. 2020 Jul;16:1-2. DOI: 10.1080/09546634.2020.1795062.
- 20 De Giorgi V, Recalcati S, Jia Z, Chong W, Ding R, Deng Y, et al. Cutaneous manifestations related to coronavirus disease 2019 (COVID-19): A prospective study from China and Italy. *J Am Acad Dermatol*. 2020 Aug;83(2):674-5.
- 21 Rivera-Oyola R, Koschitzky M, Printy R, Liu S, Stanger R, Golant AK, et al. Dermatologic findings in 2 patients with COVID-19. *JAAD Case Rep*. 2020 Apr;6(6):537-9.
- 22 Jimenez-Cauhe J, Ortega-Quijano D, Prieto-Barrios M, Moreno-Arrones OM, Fernandez-Nieto D. Reply to "COVID-19 can present with a rash and be mistaken for dengue"; petechial rash in a patient with COVID-19 infection. *J Am Acad Dermatol*. 2020 Aug;83(2):e141-2.
- 23 Najarian DJ. Morbilliform exanthem associated with COVID-19. *JAAD Case Rep*. 2020 Apr;6(6):493-4.
- 24 Català A, Galván-Casas C, Carretero-Hernández G, Rodríguez-Jiménez P, Fernández-Nieto D, Rodríguez-Villa A, et al. Maculopapular eruptions associated to COVID-19: A sub-analysis of the COVID-Piel study [Online ahead of print]. *Dermatol Ther (Heidelb)*. 2020 Aug:e14170.
- 25 Gianotti R, Veraldi S, Recalcati S, Cusini M, Ghislanzoni M, Boggio F, et al. Cutaneous Clinico-Pathological Findings in three COVID-19-Positive Patients Observed in the Metropolitan Area of Milan, Italy. *Acta Derm Venereol*. 2020 Apr;100(8):adv00124-2.
- 26 Reymundo A, Fernández-Bernaldez A, Reolid A, Butrón B, Fernández-Rico P, Muñoz-Hernández P, et al. Clinical and histological characterization of late appearance maculopapular eruptions in association with the coronavirus disease 2019. A case series of seven patients. *J Eur Acad Dermatol Venereol*. 2020 Jun;jdv.16707.
- 27 Herrero-Moyano M, Capusan TM, Andreu-Barasoain M, Alcántara-González J, Ruano-Del Salado M, Sánchez-Largo Uceda ME, et al. A clinicopathological study of eight patients with COVID-19 pneumonia and a late-onset exanthema. *J Eur Acad Dermatol Venereol*. 2020 May;34(9): <https://doi.org/10.1111/jdv.16631>.
- 28 Marzano AV, Genovese G, Fabbrocini G, Piggatto P, Monfrecola G, Piraccini BM, et al. Varicella-like exanthem as a specific COVID-19-associated skin manifestation: multicenter case series of 22 patients. *J Am Acad Dermatol*. 2020 Jul;83(1):280-5.
- 29 Askin O, Altunkalem RN, Altinisk DD, Uzuncakmak TK, Tursen U, Kutlubay Z. Cutaneous manifestations in hospitalized patients diagnosed as COVID-19. *Dermatol Ther (Heidelb)*. 2020 Jun;24:e13896.
- 30 Genovese G, Colonna C, Marzano AV. Varicella-like exanthem associated with COVID-19 in an 8-year-old girl: A diagnostic clue? *Pediatr Dermatol*. 2020 May;37(3):435-6.
- 31 Fernandez-Nieto D, Ortega-Quijano D, Jimenez-Cauhe J, Burgos-Blasco P, de Perosanz-Lobo D, Suarez-Valle A, et al. Clinical and histological characterization of vesicular COVID-19 rashes: a prospective study in a tertiary care hospital. *Clin Exp Dermatol*. 2020 May;45(7):872-5.
- 32 Mahé A, Birckel E, Merklen C, Lefèbvre P, Hannedouche C, Jost M, et al. Histology of skin lesions establishes that the vesicular rash associated with COVID-19 is not 'varicella-like'. *J Eur Acad Dermatol Venereol*. 2020 Oct;34(10):e559-61.
- 33 Trellu LT, Kaya G, Alberto C, Calame A, McKee T, Calmy A. Clinicopathological Aspects of a Papulovesicular Eruption in a Patient With COVID-19. *JAMA Dermatol*. 2020 Aug;156(8):922-4.
- 34 Tammamo A, Adebajo GA, Parisella FR, Pezzuto A, Rello J. Cutaneous manifestations in COVID-19: the experiences of Barcelona and Rome. *J Eur Acad Dermatol Venereol*. 2020 Jul;34(7):e306-7.
- 35 Elsaie ML, Nada HA. Herpes zoster (shingles) complicating the course of COVID-19 infection. *J Dermatolog Treat*. DOI: 10.1080/09546634.2020.1782823. Epub 2020 Oct 12.
- 36 Lim SY, Tey HL. Response to 'Classification of the cutaneous manifestations of COVID-19: a rapid prospective nationwide consensus study in Spain with 375 cases': vesicular eruption in COVID-19 - to exclude varicella. *Br J Dermatol*. 2020 Oct;183(4):790-1.
- 37 Llamas-Velasco M, Rodríguez-Jiménez P, Chicharro P, De Argila D, Muñoz-Hernández P, Daudén E. Reply to "Varicella-like exanthem as a specific COVID-19-associated skin manifestation: Multicenter case series of 22 patients": To consider varicella-like exanthem associated with COVID-19, virus varicella zoster and virus herpes simplex must be ruled out. *J Am Acad Dermatol*. 2020 Sep;83(3):e253-4.
- 38 Marzano AV, Genovese G. Response to: "Reply to 'Varicella-like exanthem as a specific COVID-19-associated skin manifestation: multicenter case series of 22 patients': To consider varicella-like exanthem associated with COVID-19, virus varicella zoster and virus herpes simplex must be ruled out." *J Am Acad Dermatol*. 2020 Sep;83(3):e255-e256.
- 39 Mazzotta F, Troccoli T. Acute acro-ischemia in the child at the time of COVID-19. *Eur J Pediatr Dermatol*. 2020;30(2):71-4.
- 40 Colonna C, Genovese G, Monzani NA, Picca M, Boggio F, Gianotti R, et al. Outbreak of chilblain-like acral lesions in children in the metropolitan area of Milan, Italy, during the COVID-19 pandemic. *J Am Acad Dermatol*. 2020 Sep;83(3):965-9.
- 41 Alramthan A, Aldaraji W. Two cases of COVID-19 presenting with a clinical picture resembling chilblains: first report from the Middle East. *Clin Exp Dermatol*. 2020 Aug;45(6):746-8.
- 42 Fernandez-Nieto D, Jimenez-Cauhe J, Suarez-Valle A, Moreno-Arrones OM, Saceda-Corralo D, Arana-Raja A, et al. Characterization of acute acral skin lesions in nonhospitalized patients: A case series of 132 patients during the COVID-19 outbreak. *J Am Acad Dermatol*. 2020 Jul;83(1):e61-3.
- 43 Bouaziz JD, Duong TA, Jachiet M, Velter C, Lestang P, Cassius C, et al. Vascular skin symptoms in COVID-19: a French observational study. *J Eur Acad Dermatol Venereol*. 2020 Apr;34(9): <https://doi.org/10.1111/jdv.16544>.
- 44 de Masson A, Bouaziz JD, Sulimovic L, Cassius C, Jachiet M, Ionescu MA, et al.; SNDV (French National Union of Dermatologists-Venereologists). Chilblains is a common cutaneous finding during the COVID-19 pandemic: A retrospective nationwide study from France. *J Am Acad Dermatol*. 2020 Aug;83(2):667-70.
- 45 Cordoro KM, Reynolds SD, Wattier R, McCalmont TH. Clustered cases of acral pernio: clinical features, histopathology, and relationship to COVID-19. *Pediatr Dermatol*. 2020 May;37(3):419-23.
- 46 Fernandez-Nieto D, Ortega-Quijano D, Suarez-Valle A, Burgos-Blasco P, Jimenez-Cauhe J, Fernandez-Guarino M. Comment on: "To consider varicella-like exanthem associated with COVID-19, virus varicella zoster and virus herpes simplex must be ruled out. Characterization of herpetic lesions in hospitalized COVID-19 patients". *J Am Acad Dermatol*. 2020 Sep;83(3):e257-9.

- 47 Freeman EE, McMahon DE, Lipoff JB, Rosenbach M, Kovarik C, Takeshita J, et al.; American Academy of Dermatology Ad Hoc Task Force on COVID-19. Pernio-like skin lesions associated with COVID-19: A case series of 318 patients from 8 countries. *J Am Acad Dermatol*. 2020 Aug;83(2):486–92.
- 48 Deutsch A, Blasiak R, Keyes A, Wu J, Marmon S, Asrani F, et al. Covid toes: phenomenon or epiphenomenon? *J Am Acad Dermatol*. 2020; 83(5):e347–e348.
- 49 Zhou Z, Ren L, Zhang L, Zhong J, Xiao Y, Jia Z, et al. Overly exuberant innate immune response to SARS-CoV-2 infection. *SSRN Electronic J*. 2020; DOI: 10.2139/ssrn.3551623.
- 50 Kaya G, Kaya A, Saurat JH. Clinical and Histopathological Features and Potential Pathological Mechanisms of Skin Lesions in COVID-19: review of the Literature. *Dermatopathology (Basel)*. 2020 Jun;7(1):3–16.
- 51 Piccolo V, Neri I, Filippeschi C, Oranges T, Argenziano G, Battarra VC, et al. Chilblain-like lesions during COVID-19 epidemic: a preliminary study on 63 patients. *J Eur Acad Dermatol Venereol*. 2020 Jul;34(7):e291–3.
- 52 Proietti I, Tolino E, Bernardini N, Mambrin A, Balduzzi V, Marchesiello A, et al. Auricle pernio-like lesions as a manifestation of Covid-19 infection. *Dermatol Ther (Heidelb)*. 2020 Jul;e14089.
- 53 Navarro L, Andina D, Noguera-Morel L, Hernández-Martín A, Colmenero I, Torrelo A. Dermoscopy features of COVID-19-related chilblains in children and adolescents. *J Eur Acad Dermatol Venereol*. 2020 Jul;jdv.16800.
- 54 Kanitakis J, Lesort C, Danset M, Jullien D. Chilblain-like acral lesions during the COVID-19 pandemic (“COVID toes”): Histologic, immunofluorescence, and immunohistochemical study of 17 cases. *J Am Acad Dermatol*. 2020 Sep;83(3):870–5.
- 55 Locatelli AG, Robustelli Test E, Vezzoli P, Carugno A, Moggio E, Consonni L, et al. Histologic features of long-lasting chilblain-like lesions in a paediatric COVID-19 patient. *J Eur Acad Dermatol Venereol*. 2020 Aug; 34(8):e365–8.
- 56 Caselli D, Chironna M, Loconsole D, Nigri L, Mazzotta F, Bonamonte D, et al. No evidence of SARS-CoV-2 infection by polymerase chain reaction or serology in children with pseudo-chilblain [Online ahead of print]. *Br J Dermatol*. 2020 Oct;183(4):784–5.
- 57 Herman A, Peeters C, Verroken A, Tromme I, Tennstedt D, Marot L, et al. Evaluation of Chilblains as a Manifestation of the COVID-19 Pandemic. *JAMA Dermatol*. 2020 Sep; 156(9):998–1003.
- 58 Docampo-Simón A, Sánchez-Pujol MJ, Juan-Carpena G, Palazón-Cabanes JC, Vergara-De Caso E, Berbegal L, et al. Are chilblain-like acral skin lesions really indicative of COVID-19? A prospective study and literature review. *J Eur Acad Dermatol Venereol*. 2020 May; 34(9): <https://doi.org/10.1111/jdv.16665>.
- 59 Denina M, Pellegrino F, Morotti F, Coppo P, Bonsignori IM, Garazzino S, et al. All that glitters is not COVID: low prevalence of seroconversion against SARS-CoV-2 in a pediatric cohort of patients with chilblain-like lesions. *J Am Acad Dermatol*. 2020 Dec;83(6):1751–53.
- 60 Ko CJ, Harigopal M, Damsky W, Gehlhausen JR, Bosenberg M, Patrignelli R, et al. Perniosis during the COVID-19 pandemic: negative anti-SARS-CoV-2 immunohistochemistry in six patients and comparison to pernio-like lesions before the emergence of SARS-CoV-2 [Online ahead of print]. *J Cutan Pathol*. 2020 Aug; 47(11):997–1002.
- 61 Le Cleach L, Dousset L, Assier H, Fourati S, Barbarot S, Boulard C, et al.; French Society of Dermatology. Most chilblains observed during the COVID-19 outbreak occur in patients who are negative for COVID-19 on polymerase chain reaction and serology testing. *Br J Dermatol*. 2020 Nov;183(5):866–74.
- 62 Lesort C, Kanitakis J, Villani A, Ducroux E, Bouschon P, Fattouh K, et al. COVID-19 and outbreak of chilblains: are they related? *J Eur Acad Dermatol Venereol*. 2020 Jun;jdv.16779.
- 63 Roca-Ginés J, Torres-Navarro I, Sánchez-Arriaza J, Abril-Pérez C, Sabalza-Baztán O, Pardo-Granell S, et al. Assessment of Acute Acral Lesions in a Case Series of Children and Adolescents During the COVID-19 Pandemic. *JAMA Dermatol*. 2020 Sep;156(9):992–7.
- 64 Colmenero I, Santonja C, Alonso-Riaño M, Noguera-Morel L, Hernández-Martín A, Andina D, et al. SARS-CoV-2 endothelial infection causes COVID-19 chilblains: histopathological, immunohistochemical and ultrastructural study of seven paediatric cases. *Br J Dermatol*. 2020 Oct;183(4):729–37.
- 65 Ladha MA, Luca N, Constantinescu C, Naert K, Ramien ML. Approach to chilblains during the COVID-19 pandemic. *J Cutan Med Surg*. 2020 Sep/Oct;24(5):504–17.
- 66 Griffiths C, Barker J, Bleiker T, Chalmers R, Creamer D. *Rook's textbook of dermatology*. 9th ed, rev. Hoboken: Wiley-Blackwell; 2016.
- 67 Khalil S, Hinds BR, Manalo IF, Vargas IM, Mallela S, Jacobs R. Livedo reticularis as a presenting sign of severe acute respiratory syndrome coronavirus 2 infection. *JAAD Case Rep*. 2020 Sep;6(9):871–4.
- 68 Manalo IF, Smith MK, Cheeley J, Jacobs R. A dermatologic manifestation of COVID-19: transient livedo reticularis. *J Am Acad Dermatol*. 2020 Aug;83(2):700.
- 69 Verheyden M, Grosber M, Gutermuth J, Velkeniers B. Relapsing symmetric livedo reticularis in a patient with COVID-19 infection. *J Eur Acad Dermatol Venereol*. 2020 Jun;jdv.16773.
- 70 Chibane S, Gibeau G, Poulin F, Tessier P, Goulet M, Carrier M, et al. Hyperacute multi-organ thromboembolic storm in COVID-19: a case report. *J Thromb Thrombolysis*. 2020 Jun;6:1–4.
- 71 Drosch C, Do MH, DeSancho M, Lee EJ, Magro C, Harp J. Livedoid and Purpuric Skin Eruptions Associated With Coagulopathy in Severe COVID-19. *JAMA Dermatol*. 2020 Sep;156(9):1–3.
- 72 Bosch-Amate X, Giavedoni P, Podlipnik S, Andreu-Febrer C, Sanz-Beltran J, Garcia-Herrera A, et al. Retiform purpura as a dermatological sign of coronavirus disease 2019 (COVID-19) coagulopathy. *J Eur Acad Dermatol Venereol*. 2020 Oct;34(10):e548–9.
- 73 Magro C, Mulvey JJ, Berlin D, Nuovo G, Salvatore S, Harp J, et al. Complement associated microvascular injury and thrombosis in the pathogenesis of severe COVID-19 infection: A report of five cases. *Transl Res*. 2020 Jun;220:1–13.
- 74 Magro C, Mulvey JJ, Laurence J, Sanders S, Crowson N, Grossman M, et al. The differing pathophysiologies that underlie COVID-19 associated pernio-like and thrombotic retiform purpura: a case series. *Br J Dermatol*. 2020 Jul;bjd.19415.
- 75 Cugno M, Meroni PL, Gualtierotti R, Griffini S, Grovetti E, Torri A, et al. Complement activation in patients with COVID-19: A novel therapeutic target. *J Allergy Clin Immunol*. 2020 Jul;146(1):215–7.
- 76 Joob B, Wiwanitkit V. COVID-19 can present with a rash and be mistaken for dengue. *J Am Acad Dermatol*. 2020 May;82(5):e177.
- 77 Negrini S, Guadagno A, Greco M, Parodi A, Burlando M. An unusual case of bullous haemorrhagic vasculitis in a COVID-19 patient. *J Eur Acad Dermatol Venereol*. 2020 Jun;jdv.16760.
- 78 Del Giudice P, Boudoumi D, Le Guen B, Reverte M, Gutnecht J, Lacour JP, et al. Catastrophic acute bilateral lower limbs necrosis associated with COVID-19 as a likely consequence of both vasculitis and coagulopathy. *J Eur Acad Dermatol Venereol*. 2020 Jun;jdv.16763.
- 79 Caputo V, Schroeder J, Rongioletti F. A generalized purpuric eruption with histopathologic features of leucocytoclastic vasculitis in a patient severely ill with COVID-19. *J Eur Acad Dermatol Venereol*. 2020 Oct; 34(10):e579–81.
- 80 Karaca Z, Yayli S, Çalışkan O. A unilateral purpuric rash in a patient with COVID-19 infection. *Dermatol Ther (Heidelb)*. 2020 Jul; 33(4):e13798.
- 81 García-Gil MF, Monte Serrano J, García García M, Barra Borao V, Matovelle Ochoa C, Ramirez-Lluch M, et al. Acral purpuric lesions associated with coagulation disorders during the COVID-19 pandemic. *Int J Dermatol*. 2020 Sep;59(9):1151–2.
- 82 Larrondo J, Cabrera R, Gosch M, Larrondo F, Aylwin M, Castro A. Papular-purpuric exanthem in a COVID-19 patient: clinical and dermoscopic description. *J Eur Acad Dermatol Venereol*. 2020 Oct;34(10):e570–2.
- 83 Jimenez-Cauhe J, Ortega-Quijano D, Carrettero-Barrio I, Suarez-Valle A, Saceda-Corralo D, Moreno-García Del Real C, et al. Erythema multiforme-like eruption in patients with COVID-19 infection: clinical and histological findings. *Clin Exp Dermatol*. 2020 May;45(7): 892–5.

- 84 Ehsani AH, Nasimi M, Bigdelo Z. Pityriasis rosea as a cutaneous manifestation of COVID-19 infection. *J Eur Acad Dermatol Venereol*. 2020 May;34(9):<https://doi.org/10.1111/jdv.16579>.
- 85 Gupta A, Gill A, Sharma M, Garg M. Multi-System Inflammatory Syndrome in a Child Mimicking Kawasaki Disease. *J Trop Pediatr*. 2020 Aug;fmaa060.
- 86 Shanshal M. COVID-19 related anagen effluvium. *J Dermatolog Treat*. 2020 Jul;16:1–2. DOI: 10.1080/09546634.2020.1792400.
- 87 Llamas-Velasco M, Chicharro P, Rodríguez-Jiménez P, Martos-Cabrera L, De Argila D, Fernández-Figueras M, et al. Comment on 'Clinical and histological characterization of vesicular COVID-19 rashes: a prospective study in a tertiary care hospital'. Pseudoherpetic Grover disease seems to occur in patients with COVID-19 infection. *Clin Exp Dermatol*. 2020 May;45(7):896–8.
- 88 Almutairi A, Alfaleh M, Alasheikh M. Dermatological Manifestations in Patients With SARS-CoV-2: A Systematic Review. *Cureus*. 2020 Jul;12(7):e9446.
- 89 Seirafianpour F, Sodagar S, Pour Mohammad A, Panahi P, Mozafarpour S, Almasi S, et al. Cutaneous manifestations and considerations in COVID-19 pandemic: A systematic review. *Dermatol Ther (Heidelb)*. 2020 Jul;e13986.
- 90 Zhao Q, Fang X, Pang Z, Zhang B, Liu H, Zhang F. COVID-19 and cutaneous manifestations: a systematic review. *J Eur Acad Dermatol Venereol*. DOI: 10.1111/jdv.16778. Epub 2020 Jun 28.
- 91 Wang Y, Fang R, Zhang H, Tang K, Sun Q. Contributions of dermatologists to COVID-19 research: A brief systematic review. *Dermatol Ther (Heidelb)*. 2020 Jul;33(4):e13713.
- 92 Criado PR, Abdalla BM, de Assis IC, van Blarcum de Graaff Mello C, Caputo GC, Vieira IC. Are the cutaneous manifestations during or due to SARS-CoV-2 infection/COVID-19 frequent or not? Revision of possible pathophysiological mechanisms. *Inflamm Res*. 2020 Aug;69(8):745–56.
- 93 Novak N, Peng W, Naegeli MC, Galván C, Kolm-Djamei I, Brüggem C, et al. SARS-CoV-2, COVID-19, skin and immunology - What do we know so far? *Allergy*. 2020 Jul;all.14498.
- 94 Herman A, Matthews M, Mairlot M, Nobile L, Fameree L, Jacquet LM, et al. Drug reaction with eosinophilia and systemic symptoms syndrome in a patient with COVID-19. *J Eur Acad Dermatol Venereol*. 2020 Jul;jdv.16838.
- 95 Delaleu J, Deniau B, Battistella M, de Masson A, Bensaid B, Jachiet M, et al. Acute generalized exanthematous pustulosis induced by hydroxychloroquine prescribed for COVID-19. *J Allergy Clin Immunol Pract*. 2020 Sep;8(8):2777–9.